

Is Marginal Bone Loss around Oral Implants the Result of a Provoked Foreign Body Reaction?

Tomas Albrektsson, MD, PhD, RCPSG;^{*,†} Christer Dahlin, DDS, PhD;^{*,‡} Torsten Jemt, DDS, PhD;^{§,||} Lars Sennerby, DDS, PhD;[‡] Alberto Turri, DDS, PhD cand;^{*,||} Ann Wennerberg, DDS, PhD[†]

ABSTRACT

Background: When a foreign body is placed in bone or soft tissue, an inflammatory reaction inevitably develops. Hence, osseointegration is but a foreign body response to the implant, which according to classic pathology is a chronic inflammatory response and characterized by bone embedding/separation of the implant from the body.

Purpose: The aim of this paper is to suggest an alternative way of looking at the reason for marginal bone loss as a complication to treatment rather than a disease process.

Materials and Methods: The present paper is authored as a narrative review contribution.

Results: The implant-enveloping bone has sparse blood circulation and is lacking proper innervation in clear contrast to natural teeth that are anchored in bone by a periodontal ligament rich in blood vessels and nerves. Fortunately, a balanced, steady state situation of the inevitable foreign body response will be established for the great majority of implants, seen as maintained osseointegration with no or only very little marginal bone loss. Marginal bone resorption around the implant is the result of different tissue reactions coupled to the foreign body response and is not primarily related to biofilm-mediated infectious processes as in the pathogenesis of periodontitis around teeth. This means that initial marginal bone resorption around implants represents a reaction to treatment and is not at all a disease process. There is clear evidence that the initial foreign body response to the implant can be sustained and aggravated by various factors related to implant hardware, patient characteristics, surgical and/or prosthodontic mishaps, which may lead to significant marginal bone loss and possibly to implant failure. Admittedly, once severe marginal bone loss has developed, a secondary biofilm-mediated infection may follow as a complication to the already established bone loss.

Conclusions: The present authors regard researchers seeing marginal bone loss as a periodontitis-like disease to be on the wrong track; the onset of marginal bone loss around oral implants depends in reality on a dis-balanced foreign body response.

KEY WORDS: bone loss, dental implants, foreign body reaction, osseointegration, peri-implantitis

^{*}Department of Biomaterials, Göteborg University, Göteborg, Sweden; [†]Department of Prosthodontics, Malmö University, Malmö, Sweden; [‡]Department of Oral & Maxillofacial Surgery, NU Hospital Group, Trollhättan, Sweden; [§]Department of Prosthetic Dentistry/Dental Material Science, University of Göteborg, Göteborg, Sweden; ^{||}The Brånemark Clinic, Public Dental Health Service, Göteborg, Sweden; [‡]Department of Oral and Maxillofacial Surgery, Göteborg University, Göteborg, Sweden

Reprint requests: Professor Tomas Albrektsson, Department of Biomaterials, Sahlgrenska Academy, PO Box 412, Göteborg SE 405 30, Sweden; e-mail: tomas.albrektsson@gu.se

© 2013 Wiley Periodicals, Inc.

DOI 10.1111/cid.12142

INTRODUCTION

Osseointegration was discovered when working with implants in research animals¹ at the very same laboratory of the Göteborg University where the senior authors behind this publication were once trained. The discovery was made around 1962, and it has meant an enormous advancement for clinical treatment of oral implants. The advent of osseointegration represented a true clinical breakthrough; for the first time ever, reliable long-term clinical results of oral implants were reported.¹⁻³ As a reflection of the substantial contribution to clinical development we have seen with oral

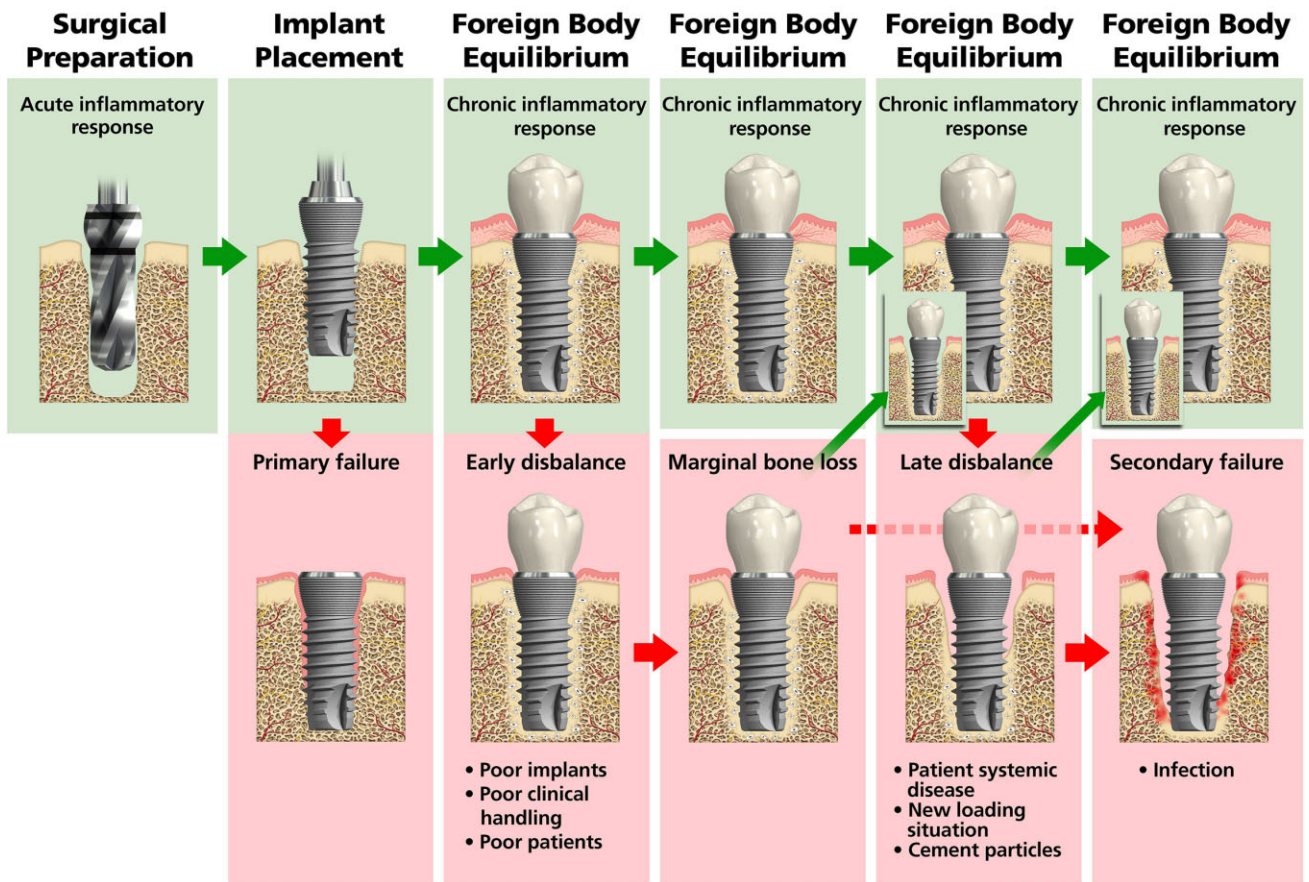


Figure 1 Events occurring when an oral implant is placed in the jaw bone. A foreign body reaction is inevitable; good clinical results follow the establishment of a foreign body equilibrium. However, the equilibrium may be disturbed by unsuitable implants, improper clinical handling, various adverse patient factors, remnants of cement or new loading situations which, acting together, may result in marginal bone loss around the implant. A reestablishment of the foreign body equilibrium is possible, but if this does not occur, implants will lose gradually more bone and may eventually fail.

implants, thousands and thousands again of patients have benefitted from osseointegration. Although no reliable documentation exists, it has been estimated that approximately 12 million osseointegrated oral implants are placed annually in a global perspective. In the light of this tremendous clinical success, the dissection of osseointegration under a critical histopathological analysis is indeed a delicate task.

Our aim is (1) to describe histopathological and clinical events when an implant is placed in the mandible or maxilla of patients, (2) to discuss different suggested mechanisms behind marginal bone loss around oral implants, (3) to perform a resumé of previous research efforts on implants and foreign body responses to them, (4) to critically analyze whether threats to osseointegration such as the initiation of marginal bone loss is a mirror image of what happens to teeth, and (5) to summarize how we, from a clinical aspect, best

maintain the foreign body equilibrium represented by osseointegration.

When an oral implant is to be placed in bone (Figure 1), the sequence starts by preparing the defect. Surgical preparation results in breakage of blood vessels, destruction of bone tissue with a necrotic border zone inevitably developing,⁴ and an *acute inflammatory response* following. The latter is an important step in the healing cascade leading to the preferred bony anchorage of the implant. Thereafter, two possible events follow the placement of the implant: Either a foreign body response develops, characterized by a chronic inflammatory response with the implant shielded off from the rest of the organism by an enveloping bone tissue layer that gradually condenses,⁵ or, for reasons not fully known, the foreign body response results in the implant being embedded (encapsulated) in soft tissues, thereby representing a *primary clinical failure*. The latter problem is

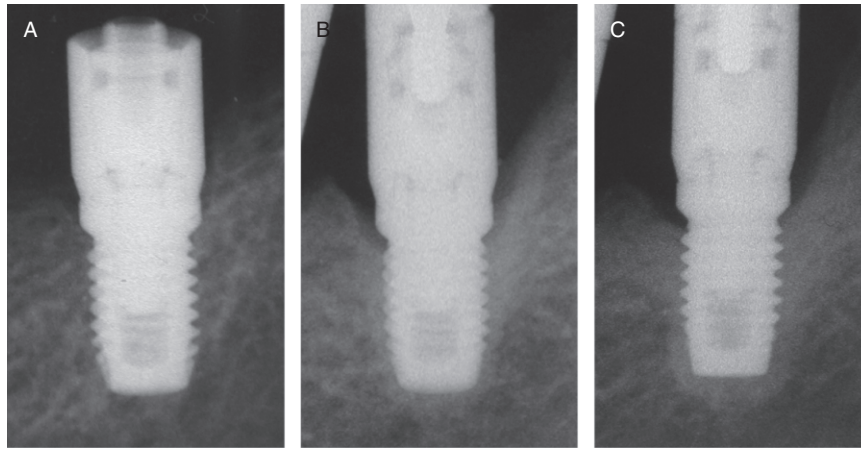


Figure 2 The foreign body response around any oral implant may be noticeable in radiograms of successful implants. In A, the implant is seen immediately after placement. In B, we see the same implant at 2 years after placement with a clear condensation around it. C depicts the same implant at 8 years with a condensed bone layer found in many foreign body situations.

rare with modern implants placed by trained clinicians but was a more common problem in the infancy of osseointegration.¹ The following events may likewise follow two possible routes: *the foreign body equilibrium* with a mild chronic inflammation (that we call osseointegration) or a resulting *early dis-balance* where bone resorption dominates over bone formation and where the inevitable chronic inflammatory state is activated. In contrast, the foreign body equilibrium is characterized by a steady state situation in the bone and only a mild chronic inflammation. By time, the bone encapsulated implant will be covered by an increasingly thicker bone layer, especially observed at the crestal part of the implant⁶ (Figure 2) Similar encapsulation of foreign bodies may be observed in primitive animals such as the pearl oyster or fruit fly.⁷ There is evidence from the literature that the unwanted dis-balance is triggered by using nonoptimal implant designs, traumatic clinical handling, and by placing implants in anatomically and/or medically compromised sites of patients,⁸ with other words it represents a clinical complication not a disease process. Furthermore, systemic, general health aspects have been associated with this unfavorable response in the peri-implant bone.⁹ In the case of a *continued foreign body response equilibrium*, all is fine from a clinical standpoint, whereas the dis-balance situation results in marginal bone loss with time, possibly leading to micromovements of the implant.⁸ Lamentably, there are cases where a *late disbalance* occurs, for example, because of developing systemic disease of the patient to remnants of cement particles in the soft tissues or to a new loading situation, for example, if

nearby teeth have failed. This late dis-balance may lead to *marginal bone loss and micromovements* as well as an increasing inflammatory response in the same manner as seen with the early dis-balance. However, a dis-balance, whether early or late, need not result in clinical failure; for example, in the case of removed cement particles in soft tissues another foreign body equilibrium may result, if with some bone resorption around the implant. Infection is a late response to already dis-balanced implants. It cannot at all be compared to the infection seen around teeth that we term periodontitis. The question in the implant case is whether infection really has any true implications for the fate of the implant. In contrast, in the good clinical case, osseointegration remains undisturbed, that is, a continued balance in form of foreign body equilibrium, which has been documented over 20 years or more in oral implantology.¹⁰

Alternative Mechanisms behind Marginal Bone Resorption

The authors of the present paper see marginal bone loss around oral implants as a consequence of an aggravated foreign body response inevitable when placing foreign materials in bone. It is, in fact, impossible to understand original reasons for marginal bone loss without realizing the histopathological background: the role of the type of foreign body reaction that we term *osseointegration*. Foreign body reactions are commonly described to a number of different types of implants placed in the body but have, for one reason or the other, been so far more or less ignored in the dental implant literature with the

exception of some pioneering papers by the late German pathologist Karl Donath.^{5,11}

Marginal bone loss around oral implants has been reported in most clinical follow-up studies. In the majority of cases, marginal bone loss is a process most pronounced during the first year after placement, probably as an adaptive response to healing and loading that will not threaten implant anchorage and is not necessarily of predictive values for later changes of the bone level.¹² However, in other cases, more rapid bone loss may develop that represents a hazard for long-term survival of the implant. For many clinicians, bone resorption is seen as more or less synonymous to a biofilm-mediated infectious disease peri-implantitis.¹³ We believe this is misconceived – there is, in fact, no proper evidence that progressing bone resorption generally is initiated by any form of an infectious disease process. This was also the notion when peri-implantitis (originally coined by Levignac¹⁴ and Mombelli et al.¹⁵) became an accepted term at the first European Workshop on Periodontology in 1993.¹⁶ The term peri-implantitis was then agreed upon as a general name for destructive peri-implant inflammatory processes. In line with this, we see late significant bone loss as an unfavorable change of the clinical balance between the foreign body response and external impact/or internal host response factors.¹⁷ Having said this, if a purulent infection is present, microorganisms may be involved but not necessarily the cause for marginal bone resorption, as also pointed out by Mombelli and Décaillot.¹⁸ We are not alone in this critical attitude toward peri-implantitis as a primarily infectious disease. Koka and Zarb¹⁹ suggested that when implants lose their marginal bone support, the term *osseoseparation* should be used to separate marginal bone loss from any particular disease process. We concur with these authors about the lack of evidence behind any development of a disease as the starting point of marginal bone loss, as do Becker²⁰ and Chvartzaid and Koka²¹ who neither see any convincing evidence pointing to specific bacteria starting the process of marginal bone resorption.

On Foreign Body Responses to Implants

Pioneering research efforts on possible side effects of the foreign body response have involved deliberate injections of bacteria in sites with or without the presence of a foreign body. The research may be far away from the world of oral implants but is nevertheless important to

summarize. The first investigators incriminating foreign body reactions as important cofactors in the response to a bacterial expositions were Elek and Conen.²² These authors infected sutures (foreign bodies) with cocci bacteria in human volunteers and reported a dramatic reduction of the minimum inoculum required to produce pus compared to the situation where the stitches were immediately removed from the tissues. They reported “orange size” infectious tumors and high fever reactions in patients with the sutures but also an understandable difficulty to recruit new volunteering patients to further test foreign body reactions. Their work inspired animal studies reporting minor or no problems when mice were injected subcutaneously with staphylococci in contrast to a demonstrated bacterial multiplication at the suture sites.^{23,24}

With respect to foreign body reactions to implants, Bos²⁵ analyzed failed hip joints finding evidence of such reactions, and Thiele and colleagues²⁶ described foreign body reaction to resorbable polylactide screws used for fixation purposes. In oral implantology, the potential problem of foreign body reactions has been largely overlooked. Anderson and Rodriguez²⁷ have summarized foreign body reactions to biomaterials in a recent overview. The immune complement is dependent on a protein reaction that is the first part of the immune system that recognizes foreign bodies entering the body.²⁸ The injury inevitable when drilling in bone elicits an inflammatory cell infiltration that further results in monocyte adhesion and macrophage differentiation followed by macrophage fusion into foreign body giant cell formation.²⁷ Foreign body giant cells are routinely seen at oral implant interfaces¹¹ (Figure 3). Complement activation is likely to amplify the inflammatory reaction. Adherent macrophages and foreign body giant cells are known to lead to degradation of biomaterials with subsequent implant failure. Adherent macrophages on biomaterials may become activated in an attempt to phagocytose the implant, so-called frustrated phagocytosis. It is possible that the clinical events may be influenced by materials’ surface properties such as chemistry and topography;²⁷ furthermore, nanotopography has been found to attenuate immune complement activation.²⁸

In oral implantology, it seems essential to identify host-related as well as external risk factors for the later development of marginal bone loss that may jeopardize future osseointegration of the implant. Certainly, once

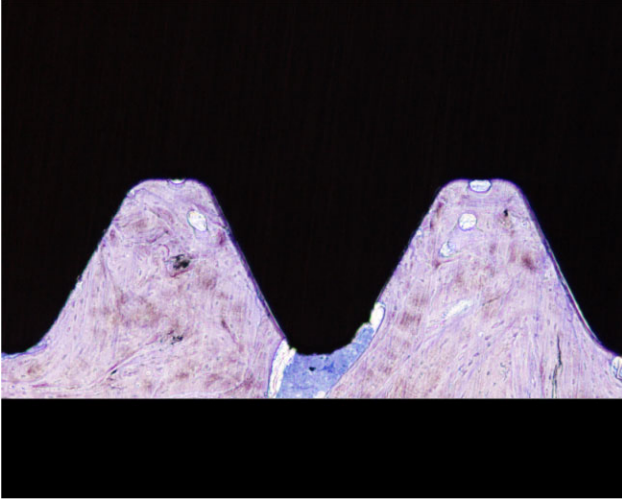


Figure 3 Foreign body giant cells are routinely found in the interface of oral implants.

peri-implantitis with or without infection has been manifested, research must be directed how to, if possible, treat the condition. However, this is not a simple endeavor, and the treatment of choice may be critically discussed.^{29,30}

When an oral implant is placed, chemistry, physical state, and electrochemical potential of the material determine the severity of the chronic inflammatory response.¹¹ Even a relatively stable material such as commercially pure titanium elicits a foreign body response in the tissues, exemplified by what we call osseointegration. It is true that osseointegration has been a positive contribution because so stabilized implants may remain in the body over long periods of time and, for example, serve as anchorage elements for a dental prosthesis, which in no way is in opposition to that the basic body reaction is one of a foreign body type. The implanted object is in a delicate balance to avoid rapid or late rejection; what will decide the outcome is dependent on the summed reactions to it.^{3,31}

More than 30 years ago, it was found imperative to more or less simultaneously control six different factors for proper osseointegration.³ These factors were (1) the biocompatibility, (2) the design and (3) the surface of the implant, (4) the status of the host bed, (5) the surgical and (6) the loading conditions. In fact, there is evidence⁸ that marginal bone resorption may follow disturbance of these factors including material shortcomings (“nonbiocompatible materials”), implant design errors resulting in high levels of marginal bone resorption, too rough or too smooth surfaces, patient

dysfunction due to hereditary problems or smoking, and clinical shortcomings in form of poor surgery and poor prosthodontics or occlusal overload.^{3,8,31–34} Typical to problems related to these factors is that the summed effect of them is more negative than would be assumed if one analyzed each one of them separately – a summation effect.^{35–38} These problems can be exemplified by experience from a recently used oral implant system where clinical recommendations in form of grinding down the implant in situ and then loading it directly were not in accordance with above-suggested biological recommendations.³⁹

What Is an Appropriate Term for Foreign Body Reactions Leading to Marginal Bone Loss?

“A day of reckoning for so called ‘peri-implantitis’ is well overdue, and it is time to expunge the term from routine use.”⁴⁰ We concur with these authors if peri-implantitis is regarded synonymous to a disease process. However, one characteristic of the foreign body reaction is that it results in a chronic inflammation. With long-term successful implants, this chronic inflammation would be of a very minor magnitude and hardly noticeable in the clinic. However, when marginal bone resorption has developed around an implant, the inflammation may be more noticeable and may eventually be further compromised by plaque accumulation and infection. A Google search on the suffix “-itis” informs that the ending is used “in pathological terms that denote inflammation.” Because an inflammatory response is characteristic of any oral implant as part of a foreign body response that is further activated in case of tissue dis-balance, we believe that the term peri-implantitis is quite appropriate, even if it is not a primary disease at all. In fact, the tissue sequel is a *complication* because of a clinically unfavorable dis-balanced foreign body reaction that is the starting point of the pathological process, nothing else.

To further elaborate on the inflammatory aspect, another dogma that needs to be addressed is the presence of suppuration or pus adjacent to implants. This has been taken as direct evidence of an ongoing infectious process adjacent to the respective implants, and subsequent active anti-infectious clinical measures have been proposed. However, if you look more closely at the definition of suppuration from an immunologic standpoint and as part of the complement activation, it is by definition of pus: “A fluid product of inflammation

consisting of a liquid containing leucocytes and the debris of dead cells and tissue elements liquefied by the proteolytic and histolytic enzymes (leukoprotease) that are elaborated by polymorphonuclear leucocytes.⁴¹ Hence, suppuration is part of an unspecific inflammatory reaction toward foreign bodies where bacteria are only one of several possible causes for the immunologic complement activation.

Mixing of Two Conceptually Different Entities – Tooth versus Foreign Body Response

Peri-implantitis as a disease entity builds on several postulates. One such postulate is that the implant and tooth are similar entities and hence, the pathogenesis of peri-implantitis is identical to that of periodontitis. Another postulate claims a situation free from inflammation at the implant in analogy with what can be expected at natural teeth, a situation that can be questioned in the light of the chronic foreign body inflammation that is inevitable around oral implants. Furthermore, claims are related to the origin of the involved microorganisms to be either an infection from the time of implant placement or a biofilm-mediated infection originating from

the soft tissue margin. Bacterial leakage from the interface between the implant body and the abutment has been another incriminated source for infectious developments (for review see Qian et al.⁸).

The notion that biofilm-mediated infection is the cause for marginal bone loss at implants derives from extrapolations of findings from experimental and clinical studies on implants and teeth. For instance, it has been demonstrated that the presence of a biofilm on implant components at the soft tissue margin induces an inflammation and that this inflammation can be reduced by removing the biofilm.⁴² Histology from dog studies has demonstrated a similar size and composition of the inflammatory infiltrate as a response to a biofilm formation at teeth and implants after 3 weeks.⁴³

Accordingly, the postulate of a similarity between implants and teeth seems a far-fetched one from a biological perspective (Figure 4.). The successful implant has an interface of bone tissue, with only minor vascularization and almost total lack of innervation in contrast to the tooth with an abundant vascularization and innervation of the periodontal ligament. Donath⁵ pointed out that the bone tissues around an implant

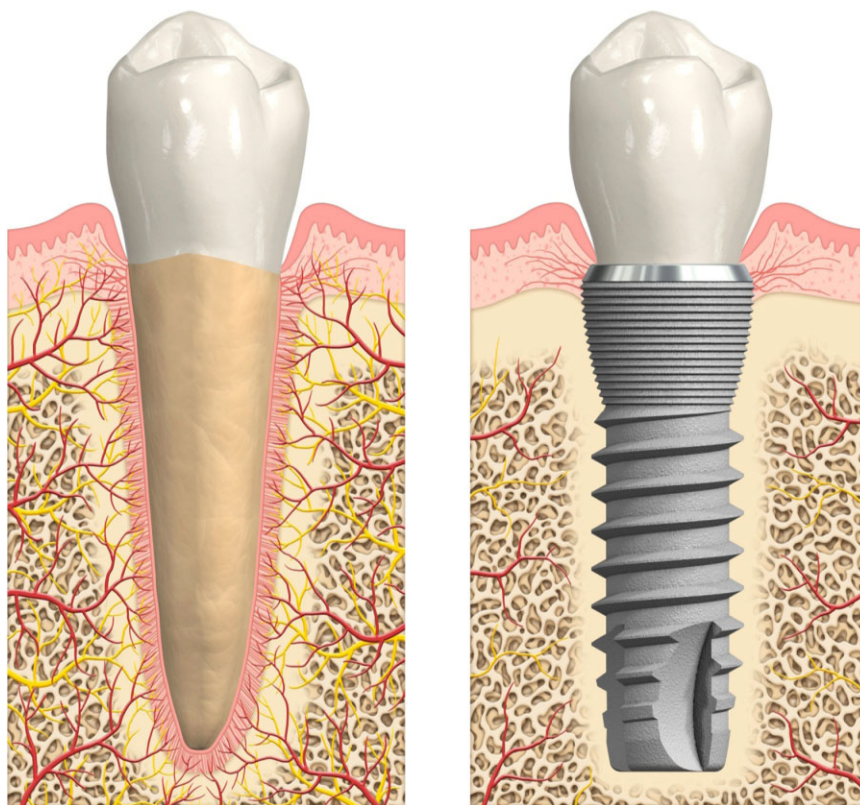


Figure 4 The tooth is anchored in a periodontal ligament characterized by rich innervation and blood perfusion. This is in sharp contrast to the implant that is anchored in foreign body bone with very sparse innervation and blood flow.

are devoid of an independent blood circulation in contrast to the gingiva of the tooth with a subepithelial and dentogingival plexus. Possibly, blood vessels are formed at the outer border of the bone capsule by time. Furthermore, the implant is stable (ankylosed), whereas the tooth is mobile. The dentogingival complex with its specialized tissues is the result of evolution, whereas the implant is constructed by outside technology. “Clinically there is a difference in the tissue reaction to the pathogenic flora. The gingiva of a natural tooth shows all the signs of inflammation with a raised secular fluid rate, while this is not the case in the mucosa around an implant . . . where the sulcular fluid rate is not elevated.”⁵

We concur with Chvartzaid and colleagues³¹ that similar tissue reactions to the greatly different interfacial situations around an implant and a tooth seem most unlikely. Not very surprisingly, the anatomical image of bone resorption due to periodontitis or peri-implantitis differs from one another, in many situations with very wide bone craters being typical for the implant but not for the tooth. When long-term, follow-up implant systems have been analyzed with respect to subgingival microbiota and compared to the outcome with the natural dentition, it was concluded in one study that subgingival plaque samples from implants did not reach the concentration of pathogens, even after 12 years of function. Furthermore, bone levels were stable with minimal bone resorption, and the presence of periopathogens did not necessarily result in bone loss.⁴⁴ A very interesting observation that strongly supports the hypothesis that marginal bone loss around implants could be linked more to a foreign body reaction and not having an infectious origin was recently described by Becker and colleagues⁴⁵ who compared transcriptome profiling using mRNA from patients suffering from either peri-implantitis or periodontitis. A gene ontology analysis revealed various pathways. In peri-implantitis tissues, the regulation of transcripts related primarily to innate immune responses and defense responses while in periodontitis bacterial response systems prevailed.

“When peri-implant tissue destruction occurs, little is known about the initiating process,” one academic periodontist wrote recently.⁴⁶ Koch’s postulate^{47,48} with the suggested revision by Fredericks and Relman⁴⁹ has not been demonstrated applicable to oral implants; the microorganism allegedly involved in peri-implantitis has not been found causing disease when introduced

into a healthy organism. This is also in line with Mombelli and Décaillot¹⁸ who concluded that microorganisms may be present but not necessarily the cause of peri-implantitis. Recent associations between systemic factors and bone loss open up for alternative factors that may disrupt the favorable biological balance.⁹

Another interesting observation follows inspection of tissue breakdown because of the alleged disease peri-implantitis where commonly, but not always, even craters seem to have formed in the bird’s eye view (Figure 5). A pure disease would in all probability result in a much more uneven anatomy of the defect. What we see instead is an even bone resorption presenting defined distances between the bone rims and the implant margins, indicative of a combined problem that may involve not only inflammation/infection but also a foreign body response that acts in combination with these other mechanisms defining the final distance from the implant that is affected by the bone resorption; that is, what is resorbed may be predominantly, if not exclusively, the foreign body bone, whereas resorption of the properly vascularized host bone is potentially lacking.

The disease explanation is furthermore most unlikely in view of numerous clinical situations documented with subsequent marginal bone loss (for review see Qian et al.⁸). It seems difficult, if not impossible, to couple such clinically observed marginal bone loss to a disease. This is exemplified by the correlation between individual clinicians and higher failure rates as well as

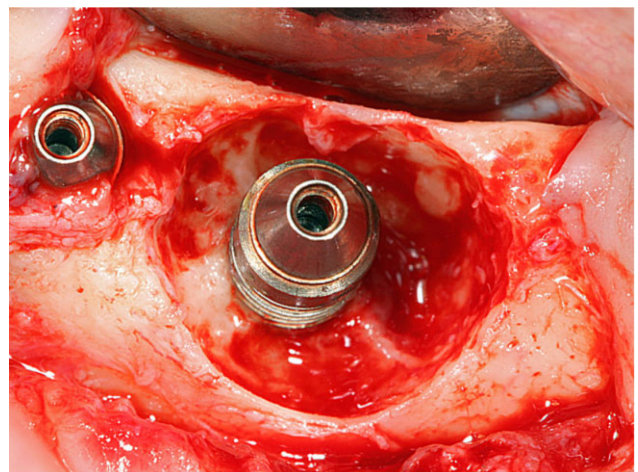


Figure 5 In many clinical cases of peri-implantitis with advanced bone resorption, we have observed that even bone craters may form if inspected in the bird’s eye view. It is possible that the even borders appear when the anchoring foreign body bone has been resorbed, whereas adjacent richly vascularized bone is more resistant to resorption.

higher levels of marginal bone resorption compared to their peers, despite them using the same implant system.^{32,33} A particular approach, to use ligatures to elicit bone resorption and infection,⁵⁰ is another example of a foreign body response, or rather two foreign body responses. Here, we have the initial foreign body response to the implant, then another foreign body in form of the ligature that is added to the implants, and it is not at all surprising that such a combined provocation will result in adverse tissue reactions in the form of marginal bone loss. With time, the inflammatory response worsens and a suprainfection may occur in what may be described as secondary peri-implantitis.⁸

How to Best Maintain a Foreign Body Equilibrium

In fact, most clinical efforts have been directed to maintaining osseointegration; that is, succeeding with having an undisturbed, if with signs of mild chronic inflammation, foreign body equilibrium. From a strict clinical results point of view, we have gradually improved clinical outcome of implants compared to the pioneering days of osseointegration.^{1,51} This clinical improvement is due to a combination of improved clinical handling and, possibly, to new improved implant types. Having said this, modern simplifications in the form of possibilities for a direct loading of implants represent a simultaneously increased clinical risk because the foreign body equilibrium may be disturbed during this early phase of function. This risk may be substantial if patients with poor bone beds are treated by poorly trained clinicians, an example of combined effects that may disturb osseointegration.⁸

From the perspective of increasing early implant success rates, the response is simple: moderately rough surfaces outperform minimally rough ones (such as turned ["machined"] Branemark implants) and rough implants (such as old plasma sprayed ones). Jimbo and Albrektsson⁵¹ compared five-year clinical outcomes for machined and moderately rough implants with a significantly enhanced failure rate for maxillary implants of the former. Olsson and colleagues⁵² analyzed the early failure rate of implants placed at the Branemark clinic between 1986 and 2010. A total of 35,444 implants were inserted with a mean incidence of early first implant failure between 1986 and 2002 being 8.95% in the maxilla and 1.84% in the mandible compared with

respectively 2.65% maxillary and 1.53% mandibular failures between 2003 to 2010. This considerable drop in maxillary failure rates coincided with the transition from "machined" to TiUnite surfaces. The list of compromising factors where improved early results have been seen to modern, moderately rough surfaces includes patient smoking, the use of short implants, previous irradiation, or bone grafting (for review see Qian et al.⁸).

We realize that improved surgical skills may positively influence clinical results in comparisons between previously and more recently published papers, even if we regard the improved early success rates with maxillary implants as described by Olsson and colleagues⁵² to point to a clear positive contribution from the new surfaces; improvements were too rapid to be explained in any other way. We further realize that many other factors than those discussed in the present Review may influence implant survival/failure including over instrumentation and high occlusal loads to mention but a few.

However, to decide "the best" surface, we cannot necessarily use figures on levels of marginal bone contact to different surfaces because we do not know the ideal such percentage of bone to implant contact. A stronger initial bone response need not be coupled to improved long-term clinical outcome, instead it may indicate a stronger foreign body reaction compared with that found to other implants, and the only way to find out whether this reaction is positive or negative would seem to be scrutiny of long-term clinical data.

Concluding Remarks

The osseointegrated interface remains in a very delicate balance where adverse individual tissue reactions may combine with the foreign body reaction to cause unwanted sequel in form of marginal bone loss or implant failure. The *locus resistens minoris* created by the foreign body reaction⁵³⁻⁵⁵ has resulted in a series of events potentially leading to implant failure.

This reasoning implies the necessity of clinical control of the implant situation. Learned and skillful clinicians would simply have better a clinical outcome than their counterparts because they will minimize setting off a cascade of triggering factors that may combine with the foreign body reactions to cause implant problems. The fact that the clinical problem of marginal bone resorption is related to by whom and how

the implant is placed makes attempted consensus statements such as assuming the frequency of peri-implantitis to be 20% of all treated patients meaningless.⁵⁶

CONCLUSIONS

- (1) There is no evidence found in the literature that the basic mechanism behind marginal bone loss to oral implants is related to periodontitis like lesions.
- (2) The initial reaction to an oral implant is of a foreign body nature of which osseointegration is an example.
- (3) The foreign body reaction inevitable when placing an oral implant may combine with various implant, clinician and patient-related factors to result in marginal bone loss and/or implant failure.
- (4) The foreign body reaction presents with a *locus resistens minoris* characterized by an increased vulnerability for the osseointegrated implant.
- (5) Secondarily, a worsened inflammatory response or even infection may develop as a complication, further threatening the implant longevity.
- (6) The use of controlled implants and skillful clinicians result in very good, long-term results of osseointegrated oral implants with a due, long-term balance of the foreign body response.
- (7) Patient factors such as a hereditary disease, consumption of certain drugs, or smoking habits may represent a threat to increased marginal bone loss despite control of implant and clinician factors.

ACKNOWLEDGMENTS

The authors are indebted to Professors Peter Thomsen and Pentti Tengwall, Department of Biomaterials, University of Göteborg for their advice and for giving valuable comments to this paper prior to submission. We are further indebted to the Sylván Foundation that has supported this research project economically.

REFERENCES

1. Brånemark PI, Hansson BO, Adell R, et al. Osseointegrated implants in the treatment of the edentulous jaw. *Scand J Plast Reconstr Surg* 1977; 11(Suppl 16):1–132.
2. Adell R, Lekholm U, Rockler B, Brånemark PI. Osseointegrated implants in the treatment of edentulousness. A 15-year follow up study. *Int J Oral Surg* 1981; 6:387–416.
3. Albrektsson T, Brånemark PI, Hansson HA, Lindström J. Osseointegrated titanium implants requirements for ensuring a long-lasting, direct bone anchorage in man. *Acta Orthop Scand* 1981; 52:155–170.
4. Eriksson A, Albrektsson T, Magnusson B. Assessment of bone viability after heat trauma. *Scand J Plast Reconstr Surg* 1984; 18:261–268.
5. Donath K. Pathogenesis of bony pocket formation around dental implants. *J Dent Assoc S Afr* 1992; 47:204–208.
6. Strid KG. Radiographic results. In: Brånemark PI, Zarb G, Albrektsson T, eds. *Tissue integrated prostheses*. Chicago, IL: Quintessence Co, 1985:187–198.
7. Lemaitre B, Hoffman J. The host defense of *Drosophila melanogaster*. *Annu Rev Immunol* 2007; 25:697–743.
8. Qian J, Wennerberg A, Albrektsson T. Reasons for marginal bone loss around oral implants. *Clin Implant Dent Relat Res* 2012; 14:792–807.
9. Friberg B, Jemt T. Rehabilitation of edentulous mandibles by means of osseointegrated implants: a 5-year follow up study on one- or two- stage surgery, number of implants, implant surfaces and age at surgery. *Clin Implant Dent Relat Res* 2013. Accepted for publication.
10. Ekelund JA, Lindquist LW, Carlsson GE, Jemt T. Implant treatment in the edentulous mandible: a prospective study on Brånemark system implants over more than 20 years. *Int J Prosthodont* 2003; 16:602–608.
11. Donath K, Laass M, Günzl HJ. The histopathology of different foreign body reactions in oral soft tissue and bone tissue. *Virchows Arch A Pathol Anat Histopathol* 1991; 420:131–137.
12. Pikner SS, Gröndahl K. Radiographic analyses of “advanced” marginal bone loss around Brånemark dental implants. *Clin Implant Dent Relat Res* 2011; 11:120–133.
13. Rosen P, Clem D, Cochran D, et al. Peri-implant mucositis and peri-implantitis: a current understanding of their diagnoses and clinical implications. *J Periodontol* 2013; 84: 436–443.
14. Levignac J. L’ostéolyse périimplantaire. Périimplantose – Périimplantite. *Rev Fr Odontostomatol* 1965; 12:1251–1260.
15. Mombelli A, Van Osten MAC, Shürach E, Lang NP. The microbiota associated with successful or failing osseointegrated titanium implants. *Oral Microbiol Immunol* 1987; 2:145–151.
16. Albrektsson T, Isidor F. Consensus report session. In: Lang NP, Karring T, eds. *Proceedings of the 1st European Workshop on periodontology*. London: Quintessence, 1993:365–369.
17. Jemt T, Gyzander V, Örnhall Britse A. Incidence of surgery related to problems with peri-implantitis. A retrospective study on patients followed up between 2003 and 2010 at one specialist clinic. *Clin Implant Dent Relat Res* 2013. (Accepted).

18. Mombelli A, Décaillet F. The characteristics of biofilms in peri-implant disease. *J Clin Periodontol* 2011; 38(Suppl 11): 203–213.
19. Koka S, Zarb G. On osseointegration: the healing adaptation principle in the context of osseosufficiency, osseoseparation and dental implant failure. *Int J Prosthodont* 2012; 25:48–52.
20. Becker W. Osseointegration: have we tinkered with the process too much?? *Clin Implant Dent Relat Res* 2012; 14:779–780.
21. Chvartzaid D, Koka S. On manufactured diseases, healthy mouths and infected minds. *Int J Prosthodont* 2011; 24:102–103.
22. Elek S, Conen P. The virulence of *Staphylococcus pyogenes* for man: a study of the problems of wound infection. *Br J Exp Pathol* 1957; 38:573–586.
23. James RC, MacLeod CJ. Introduction of staphylococcal infections in mice with inocula introduced on sutures. *Br J Exp Pathol* 1957; 38:573–586.
24. Taubler J, Kapral FA. Staphylococcal population changes in experimentally infected mice: infection with sutures – absorbed and unabsorbed organisms grown in vitro and in vivo. *J Infect Dis* 1966; 116:257–263.
25. Bos I. Gewebereaktion um gelockerte Hüftgelenkendoprothesen. *Der Orthopäde* 2001; 30:881–889.
26. Thiele A, Bilkenroth U, Bloching M, Knipping St. Fremderkörperreaktion nach implantation eines biocompatiblen Osteosynthese systeme. *HNO* 2008; 56:545–548.
27. Anderson JM, Rodriguez A, Chang DT Foreign body reaction to biomaterials. *Semin Immunol* 2008; 20:86–100.
28. Hulander M, Lundgren A, Berglin M, Ohrlander M, Lausmaa J, Elwing H. Immune complement activation is attenuated by surface nanotopography. *Int J Nanomedicine* 2011; 6:2653–2666.
29. Serino G, Turri A. Outcome of surgical treatment of peri-implantitis: results from a 2-year prospective clinical study in humans. *Clin Oral Implants Res* 2011; 22:1214–1220.
30. Charalampakis G, Rabe P, Leonhardt Å, Dahlén G. A follow up study of peri-implantitis cases after treatment. *J Clin Periodontol* 2011; 38:864–871.
31. Chvartzaid D, Koka S, Zarb G. Osseointegration failure. In: Zarb G, Albrektsson T, Baker G, et al., eds. *Osseointegration – on continuing synergies in surgery, prosthodontics, biomaterials*. Chicago, IL: Quintessence, 2008:157–164.
32. Albrektsson T. Is surgical skill more important for clinical success than changes in implant hardware? *Clin Implant Dent Relat Res* 2001; 3:174–175.
33. Bryant SR. Oral implant outcomes predicted by age- and site specific aspects of bone condition. Ph D thesis, Canada: Department of Prosthodontics, University of Toronto, 2001.
34. Fu JH, Hsu YT, Wang HL. Quantifying occlusal overload and how to deal with it to avoid marginal bone loss around implants. *Eur J Oral Implantol* 2012; 5(Suppl):S91–S103.
35. Lindquist L, Carlsson GE, Jemt T. Association between marginal bone loss around osseointegrated mandibular implants and smoking habits. A 10-year follow up study. *J Dent Res* 1997; 76:1667–1674.
36. van Steenberghe Jacobs R, Desnyder M, Maffei G, Quirynen M. The relative impact of local and endogenous patient-related factors on implant failure up to the abutment stage. *Clin Oral Implants Res* 2002; 13:617–622.
37. Alvim-Pereira F, Montes CC, Mira MT, Trevilatto PC. Genetic susceptibility to dental implant failure: a critical review. *Int J Oral Maxillofac Implants* 2008; 23:409–416.
38. Martin W, Lewis E, Nicol A. Local risk factors for implant therapy. *Int J Oral Maxillofac Implants* 2009; 24(Suppl): 28–38.
39. Albrektsson T, Gottlow J, Meirelles L, Östman PO, Rocci A, Sennerby L. Survival of NobelDirect implants: an analysis of 550 consecutively placed implants at 18 different clinical centres. *Clin Implant Dent Relat Res* 2007; 9:65–70.
40. Zarb G, Koka S. Osseointegration: promise and platitudes. *Int J Prosthodont* 2012; 25:11–12.
41. Nordqvist C. What is inflammation? What causes inflammation? *Medical New Today*. MediLexicon International 2012; 202–203.
42. Heitz-Mayfield LJA, Salvi GE, Botticello D, Mombelli A, Faddy M, Lang NP. Anti-infective treatment of peri-implant mucositis: a randomized controlled clinical trial. *Clin Oral Implants Res* 2011; 22:237–241.
43. Berglundh T, Lindhe J, Marinello C, Ericsson I, Liljenberg B. Soft tissue reaction to de novo plaque formation on implants and teeth. An experimental study in the dog. *Clin Oral Implants Res* 1992; 3:1–8.
44. Van Assche N, Pittayapat P, Jacobs R, Pauwels M, Teughels W, Quirynen M. Microbiological outcome of two screw-shaped titanium implant systems placed following a split-mouth randomized protocol, at the 12th year of follow – up after loading. *Eur J Oral Implantol* 2011; 4:103–116.
45. Becker S, Beck-Broichsitter B, Graetz C, Dörfer C, Wiltfang J, Häslér R. Peri-implantitis versus periodontitis: Functional differences indicated by Transcriptome Profiling. *Clin Implant Dent Relat Res* 2013. (In press).
46. Klinge B. Peri-implant marginal bone loss: an academic controversy or a clinical challenge. *Eur J Oral Implantol* 2012; 5(Suppl):S13–S19.
47. Koch R. Untersuchungen über Bakterien: V. Die Ätiologie der Milzbrand-Krankheit begründet auf die Entwicklungsgeschichte des Bacillus anthracis. *Cohns Beiträge Zur Biologie Der Pflanzen* 1976; 2:277–310.
48. Koch R. Über den augenblicklichen Stand der bakteriologischen Choleradiagnose. *Zeitschrift Für Hygiene und Infektionskrankheiten* 1893; 14:319–333.
49. Fredericks DN, Relman DA. Sequence-based identification of microbial pathogens: a reconsideration of Koch's postulates. *Clin Microbiol Rev* 1996; 9:18–33.

50. Lindhe J, Berglundh T, Ericsson I, Liljenberg B, Marinello C. Experimental breakdown of peri-implant and periodontal tissues. A study in the beagle dog. *Clin Oral Implants Res* 1992; 3:9–16.
51. Jimbo R, Albrektsson T. A comparison of marginal bone loss and clinical outcome between older, turned and newer, moderately rough oral implants. 2013. (Submitted).
52. Olsson M, Stenport V, Jemt T. Incidence of first implant failure in relation to implant surface – a preliminary report on early failure. *Abstr Swed Dent J* 2012; 36:221.
53. Zimmerlie W, Valdvoegel F, Vadaux P. Pathogenesis of foreign body infection: description and characteristics of an animal study. *J Infect Dis* 1982; 146:487–497.
54. Kaplan S, Basford M, Mora E, Jeong M, Simmons R. Biomaterial- induced alterations of neutrophil superoxide production. *J Biomed Mater Res* 1992; 26:1039–1051.
55. Henke PK, Bergamini T, Brittain K, Polk HC. Prostaglandin E2 modulates monocyte MCH-II(Ia) suppression in bio-material infection. *J Surg Res* 1997; 69:372–378.
56. Klinge B, Meyle J. Peri-implant tissue destruction. The Third EAO Consensus Conference 2012. *Clin Oral Implants Res* 2012; 23(Suppl 6):108–110.